

Differential diagnosis of facial pain and guidelines for management

J. M. Zakrzewska*

Facial Pain Unit, Division of Diagnostic, Surgical and Medical Sciences, Eastman Dental Hospital, UCLH NHS Foundation Trust, 256 Grays Inn Road, London WC1X 8LD, UK

* E-mail: j.zakrzewska@ucl.ac.uk

Editor's key points

- Accurate diagnosis of facial pain is the first step in successful management.
- Dental and non-dental causes are both common, with consequent difficulties in appropriate referral.
- The evidence for management is often extrapolated from other chronic pain conditions.
- Well-designed clinical trials of facial pain are needed, with clinically relevant outcome measures.

Summary. The diagnosis and management of facial pain below the eye can be very different dependant on whether the patient visits a dentist or medical practitioner. A structure for accurate diagnosis is proposed beginning with a very careful history. The commonest acute causes of pain are dental and these are well managed by dentists. Chronic facial pain can be unilateral or bilateral and continuous or episodic. The commonest non-dental pains are temporomandibular disorders (TMDs), especially musculoskeletal involving the muscles of mastication either unilaterally or bilaterally; they may be associated with other chronic pains. A very wide range of treatments are used but early diagnosis, reassurance and some simple physiotherapy is often effective in those with good coping strategies. Dentists will often make splints to wear at night. Neuropathic pain is usually unilateral and of the episodic type; the most easily recognized is trigeminal neuralgia. This severe electric shock like pain, provoked by light touch, responds best to carbamazepine, and neurosurgery in poorly controlled patients. Trauma, either major or because of dental procedures, results in neuropathic pain and these are then managed as for any other neuropathic pain. Red flags include giant cell arteritis which much be distinguished from temporomandibular disorders (TMD), especially in >50 yr olds, and cancer which can present as a progressive neuropathic pain. Burning mouth syndrome is rarely recognized as a neuropathic pain as it occurs principally in peri-menopausal women and is thought to be psychological. Chronic facial pain patients are best managed by a multidisciplinary team.

Keywords: diagnosis; facial pain; guidelines

The area from the eyes down to the lower mandible of the face is a territory shared between the medical and dental professions. The public remain confused as to who they should consult when they develop chronic pain in this area. The care pathway may be very different depending on who they consult. Dentists will refer their patients to dental schools and oral and maxillofacial surgeons, whereas general practitioners will refer to ear, nose and throat (ENT) neurology, or pain medicine. Dental pain is extremely common and it can also co-exist with other conditions. Patients with facial pain will often have other co-morbidities, including depression and chronic pain elsewhere: a biopsychosocial approach is needed for successful management.

The diagnostic criteria for orofacial pains can be found both in the International Association for the Study of Pain (IASP) classification¹ and in the International Headache Classification² (to be re-published in 2013); there are some variations between the two classifications. Very few of the criteria for facial pain have been validated by case control studies. From a clinical perspective, it may be most useful to divide chronic pain into those with continuous or episodic pain and then unilateral or bilateral, rather than using the more conventional

classifications (e.g. neuropathic and vascular) which are helpful in management (Fig. 1). It must always be remembered that facial pain can be secondary to primary cancer or a metastasis from elsewhere. It is important to attempt a diagnosis as Durham and colleagues³ have shown that lack of a diagnosis in patients with temporomandibular disorders (TMDs) impacted on sufferers' daily lives.

Approach to facial pain diagnosis

History and examination

To make an accurate diagnosis it is essential to listen to the history and allow time for the patient to complete their opening statement. The pain history needs to include details on:

- Timing: onset, duration, and periodicity.
- Location and radiation (e.g. within nerve distribution).
- Quality and severity.
- Relieving and aggravating factors (e.g. effect of hot, cold sweet foods, prolonged chewing, eating, brushing of teeth, touching the face, weather, physical activity, posture, stress, and tiredness).

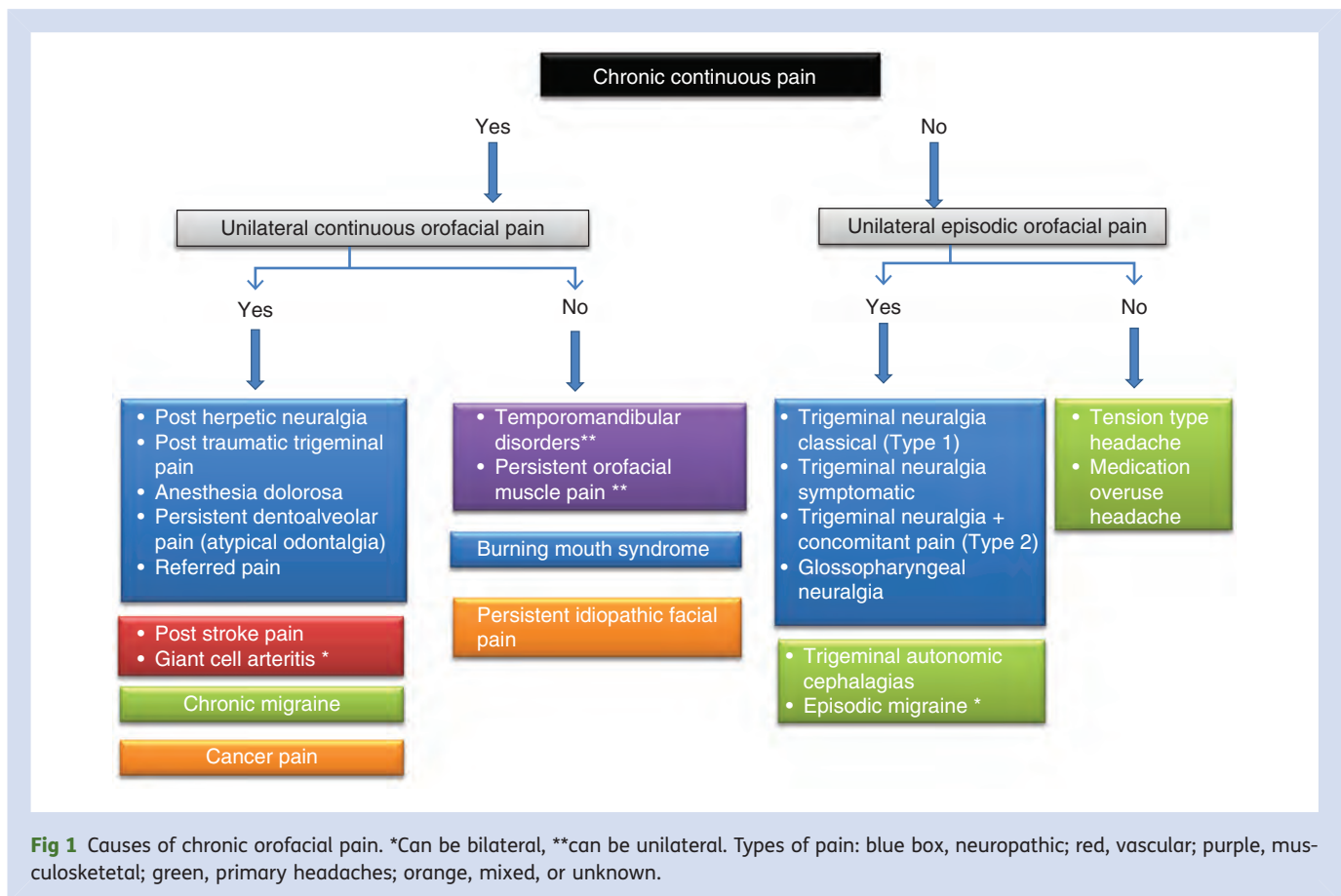


Fig 1 Causes of chronic orofacial pain. *Can be bilateral, **can be unilateral. Types of pain: blue box, neuropathic; red, vascular; purple, musculoskeletal; green, primary headaches; orange, mixed, or unknown.

- Associated factors (e.g. taste, salivary flow, clenching, bruxing habits, locking or clicking of jaw joint, altered sensation, nasal, eye, or ear symptoms).
- Other pain conditions (e.g. headaches, migraines, chronic widespread pain, and fibromyalgia).
- Impact of pain (e.g. sleep, mood, concentration, fatigue, beliefs, and quality of life).

As with all chronic pain, psychological assessment, family history (e.g. TMDs have a genetic predisposition), social history, and significant life events need to be determined. It is useful to ascertain the healthcare professionals they have accessed including complementary and alternative medicine practitioners. A full drug history is important and a past and present medical history.

Extraoral examination is confined generally to the head and neck region. Visual inspection will show up any colour changes, swellings, and skin lesions. Palpation of lumps or salivary glands may be indicated in some circumstances. Examination includes the muscles of mastication, head and neck muscles for tenderness and trigger points, muscle hypertrophy, and movement of the temporomandibular joint including crepitus. The cranial nerves need to be examined. Intraoral examination includes the hard tissues and teeth for obvious dental pathology including decay, mobile teeth, excessive wear facets (indicating bruxism), occlusion,

ability to open and fixed, and removal appliances. The oral mucosa is examined for soft tissue lesions.

Investigations

As pain is subjective, it is useful to use questionnaires to help in assessment and monitoring of effects of therapy. Questionnaires such as the Brief Pain Inventory, Beck Depression Inventory, Hospital Anxiety and Depression Scale, McGill Pain Questionnaire, and Oral Impacts on Daily Performance (OHIP) have all been well validated and are sensitive. Laboratory investigations are not of great importance, except in the potential diagnosis of cranial arteritis and for auto-immune disorders such as Sjogren's syndrome. Imaging is especially important for dental pain and consists mainly of local X-rays which can be carried out in every dental practice. Dental panoramic tomographs are very useful for bony lesions or cysts and are available in most hospitals but also in larger dental practices (for further details, see e.g. Zakrzewska⁴). Salivary gland diseases are best investigated using ultra sound. Magnetic resonance imaging (MRIs) and computerized tomography (CTs) are indicated in some conditions.

Acute facial pain

The conditions described in this section are rarely seen in pain clinics as they are relatively easy to diagnose and are effectively managed by the dental profession or general practitioners.⁵

Dental and oral causes

The majority of dental pain is acute and most are likely to be unilateral and located within the mouth, some very specifically relating to a tooth, but sometimes difficult to localize. The major features are summarized in Table 1. A good light is required to examine the teeth, the attached gingiva and then the soft tissues of the oral mucosa. If any dental causes are identified, patients need to be encouraged to seek early dental care. If they have special needs (i.e. complex medical histories or physical disabilities), they may need to be treated by dentists specializing in special needs. Diseases of the oral mucosa are painful and will be associated with a lesion (e.g. lichen planus, herpes zoster, herpes simplex, recurrent oral ulceration, and Sjogren's syndrome).⁶

Maxillary sinusitis

Most sinusitis is acute and the chronic form is less likely to be associated with pain. The International Headache Society² suggests that the diagnostic criteria for all sinusitis is the same—the only difference is location (Table 1). Acute sinusitis is most frequently caused by viruses or bacteria but it can occur after a dental infection or after treatment to upper premolar or molars, especially extractions. Dental surgical procedures can result in an oral antral fistula and patients will complain of oral and nasal discharge. Imaging may indicate the presence of a foreign body in the antrum. The fistula needs to be closed by oral/maxillofacial surgeons and then managed as for any maxillary sinusitis.

Salivary gland disorders

Tumours, duct blockage and subsequent infection of the salivary glands also elicit pain in the trigeminal nerve. Salivary stones are most frequent in the submandibular gland. The pain is intermittent and characteristically occurs just before eating. There may be associated tenderness of the involved salivary gland. Bimanual palpation will enable the stone to be palpated. If it is in the duct then salivary flow from the duct will be slow or absent. Imaging and ultrasound are useful and referral for further management to oral/maxillofacial surgeons is indicated.

Temporomandibular disorders (TMD)

By far the commonest non-dental cause of facial pain are the TMDs. They affect ~5–12% of the population and the peak age is 20–40 yr. Depression, catastrophizing, and other psychological factors increase the risk of chronicity.⁷ TMDs are also linked with back pain,⁸ fibromyalgia,^{9 10} and headaches.¹¹ Schiffman and colleagues¹² have put forward criteria for headache secondary to TMD. The large US OPPERA study confirms its complexity and that TMD is not just an isolated facial pain.^{13–15}

Dworkin and colleagues¹⁶ published the Research Diagnostic Criteria¹ for TMD in 1992 suggesting a dual axis approach, taking into account psychological factors. It has been used as a basis for research internationally. However,

it is too complex for routine clinical use and has been modified by others¹⁷ and updated (to be published in late 2013) by an international panel in order to be more clinically useful.¹⁸ Patients can have more than one diagnosis (e.g. muscle pain with or without disc displacement and limitation in opening).

The commonest form is an acute onset pain often related to prolonged opening (e.g. dental treatment or trauma). Management is reassurance, soft diet, and analgesics. Muscle pain is the commonest cause and often involves both the muscles of mastication and the neck.⁹ It is important to take a comprehensive history to elicit yellow flags as they often result in chronicity.¹⁹

The features of the masticatory form of TMD are given in Table 1. To make the diagnosis, it is crucial to appreciate that palpation needs to induce the same pain reported by the patient. Intra articular disc problems, with or without displacement, result in clicking and, if the disc does not reduce, intermittent locking. Limited opening is defined as <40 mm maximum with assisted opening (distance between the anterior incisors). Degenerative disorders present with marked crepitus (reported by the patient and detected on palpation) and are often not associated with pain. Subluxation problems are mainly found in patients with hypermobility and are associated with deviation of the jaws on opening. Imaging is not required for masticatory problems but can be useful in joint disorders to confirm the clinical findings; however, its use is controversial.²⁰

The aims of management are to decrease pain and functional limitation and improve quality of life. This is done through a wide range of therapies but overall self-management through education needs to be encouraged as improved self-efficacy leads to fewer symptoms.²¹ Therapies range from diet, splint, physiotherapy, drugs, psychological, and surgical.

RCTs and systematic reviews of treatments have been published.^{22 23} Many studies suffer from significant bias, but more recent RCTs are of higher quality.^{22 24} The primary outcome measures in most of the studies were pain; quality of life, daily activities, and psychological status were rarely reported^{23 25} even though there is good evidence that oral health related quality of life is impaired by TMD.²⁶

The most common form of therapy, carried out by dentists, is the use of a variety of intraoral appliances, mainly worn at night.²⁷ There may be some efficacy for the hard full coverage stabilization splints whereas others, which do not take into account occlusion, are prone to cause significant adverse events if misused (e.g. movement of teeth and malocclusion).^{22 25} A recent RCT suggests that, in the longer term, education may be more beneficial than splints.²⁸ Acupuncture is of limited long-term benefit^{23 29 30} and there is insufficient evidence to support the use of low level laser therapy.^{31 32} There is currently some evidence for the effectiveness of cognitive behaviour therapy (CBT)³³ and physiotherapy.^{34 35}

A Cochrane systematic review found 11 poor-quality studies on pharmacological therapy and there is inconclusive evidence for analgesics, benzodiazepines, anticonvulsants,

Table 1 Dental and musculoskeletal characteristics of facial pain

Disorder	Location radiation	Timing	Quality severity	Aggravating factors	Associated factors	Examination	Investigations	Management
DENTAL/ORAL causes								
Dental caries	Local tooth	Intermittent, length of stimuli	Dull, moderate	Hot, cold, sweet foods		Decay visible old fillings	May require intraoral X-ray	Removal caries, filling dentist
Pulpal reversible	Local tooth	Intermittent seconds to minutes	Sharp, throbbing, severe	Cold, hot, sweet foods	Caries, dental trauma	Tender to percussion, caries	Apical intraoral X-ray	Endodontics or extraction
Pulpal irreversible	Difficult to localize	Intermittent several hours	Sharp, throbbing, moderate severity	Cold, hot, sweet foods, lying supine	Caries	Tender to percussion, caries, may be gingival swelling	Apical intraoral X-ray	Endodontics or extraction
Dental sensitivity	Local affected teeth	Intermittent seconds to minutes	Sharp, moderate	Especially cold foods, air		Receded gingiva	Nil	Brushing advice, varnishes, topical fluoride
Periodontal disorders	Local teeth	Intermittent hours	Aching, dull low intensity	Eating		Mobile teeth, gingiva erythematous, pocketing, may have discharge from pocket		
Pericoronitis	Partially erupted tooth most commonly wisdom	Continuous	Aching, throbbing moderate to severe	Biting	Lymphadenopathy, malaise, fever, trismus	Tender glands, impacted tooth with redness, often upper wisdom tooth		Debridement, hot salt mouthwashes, antibiotics if systemic manifestations, extraction upper wisdom tooth initially
Premature contact	Recently restored tooth but can radiate to local ones	Intermittent on stimulation	Initially sharp, later dull	Biting	History of recent fillings			
Cracked tooth	Tooth but difficult to localize	Intermittent seconds to minutes	Sharp, sometimes dull, moderate severity	Eating, biting		Often difficult to see crack, sometimes biting on cotton wool roll will elicit pain	X-rays not always effective, may require use of dye	Dependant on location may need extraction
Alveolar osteitis (dry socket)	Local tooth socket	Continuous 4–5 days post extraction	Sharp deep ache	None	Halitosis	Loss of clot, exposed bone	Nil	Irrigation if persistent antibiotic - metronidazole
Maxillary sinusitis	Over maxillary sinus unilateral or bilateral often intraoral upper quadrant	Continuous	Dull, aching, boring, mild to moderate	Bending	Nasal discharge, history of either respiratory infection or dental treatment	Upper posterior teeth tender to percussion, tender over maxillary sinus	Occipito mental if X-ray necessary	Inhalations

Salivary stone	Submandibular area, floor of mouth or over parotid area	Intermittent	Dull, aching, moderate	Just before and while eating	Tender in the floor of the mouth. On bimanual palpation feel a stone. No salivary flow through duct	Lower occlusal radiographs	Surgical removal
TMDs							
Masticatory with or without referral to other muscles	Muscles of mastication, around and in ear radiates to temple, mouth especially retromolar area, neck. In arthralgia the pain is often more localized around the joint	Onset often sudden mostly continuous can worsen through day and night	Aching, deep but can be sharp, variable severity	Jaw movement especially prolonged chewing, opening	Clenching habit, may be associated with disc problems, often have headaches and migraines	Nil	Physiotherapy, cognitive behaviour therapy
					Tenderness and familiar pain of at least temporalis or masseter. In arthralgia tenderness also round joint itself		

and other miscellaneous drugs.³⁶ An open-label study of amitriptyline showed some benefit³⁷ whereas no benefit was noted in an RCT of Botulinum Toxin.³⁸

If there is a functional element (e.g. crepitus, limitation in movement), surgical therapies may be useful. The least invasive is arthrocentesis, a form of lavage performed under local anaesthesia but results are not maintained.³⁹ Arthroscopy is a more invasive procedure performed under general anaesthesia and allows more exploration. It can be taken a stage further to perform open surgery on the joint; this may increase functionality but relapses are common.⁴⁰ A proposed management pathway for TMD is summarized in Table 1.

Neuropathic pain

Neuropathic pain often presents on the face in the territory of the trigeminal nerve (see Table 2).

Trigeminal post herpetic neuralgia

Trigeminal post-herpetic neuralgia (PHN) has the same clinical features as other neuralgias presenting elsewhere; management should follow guidelines for neuropathic pain (e.g. O'Connor and Dworkin⁴¹).

Post traumatic trigeminal pain/trigeminal neuropathic pain/atypical odontalgia

It is being increasingly recognized that it is not just injuries such as trauma to the facial skeleton that can result in neuropathic pain of the trigeminal nerve but also various dental procedures ranging from root canal therapy and extractions to dental implants. Diagnostic criteria are being proposed.⁴²⁻⁴⁵ In cases of dentally induced injuries, there is often a history of poor analgesia at the time of the procedure when the symptoms often start. In other instances, no clear trauma can be identified and yet the pain is very clearly localized in the dental area; this has been called atypical odontalgia.⁴⁶ Currently, management is as for other neuropathic pain but there is a high percentage of failures.⁴⁷

Burning mouth syndrome

Burning mouth syndrome (BMS) is a rare chronic condition characterized by burning of the tongue and other parts of the oral mucosa in which no dental or medical causes are found. It is seen predominantly in peri- and post-menopausal women. This condition is most commonly seen by the dental profession and the oral mucosa is normal in appearance (Table 2). Neurophysiological testing, biopsies and functional MRI suggest that it is a disorder of peripheral nerve fibres⁴⁸ with central brain changes.⁴⁹ The prognosis is poor with only a small number resolving fully; however, patients can be reassured that it will not get worse and this is often crucial.⁵⁰ Secondary causes of BMS (local and systemic) include oral candidiasis, mucosal lesions, haematological disorders, auto-immune disorders, and pharmacological side-effects.

Table 2 Neuropathic and other non-dental causes of facial pain

Disorder	Location radiation	Timing	Quality severity	Aggravating factors	Associated factors	Examination	Investigations	Management
Post herpetic neuralgia	Site of herpes zoster extraoral and intraoral	Continuous	Burning, tingling, itchy, tender, can be sharp at times moderate to severe	Light touch, eating		Allodynia, hyperalgesia	Nil	Neuropathic pain medications
Post traumatic trigeminal pain/ trigeminal neuropathic	Trigeminal area at site of injury	Continuous within 3–6 months of trauma	Burning, tingling, can be sharp at times and very severe	Variety of triggers including touch, thermal, mechanical	History of dental procedure or trauma	Allodynia, or other sensory changes	Qualitative sensory testing	Neuropathic pain medications
Atypical odontalgia/ persistent dentoalveolar pain	Localized to tooth or tooth bearing area	Continuous	Aching, dull, throbbing, sometimes sharp, mild to moderate severity	Sometimes touch		May be hyperaesthesia in the area	Intraoral X-rays to ensure no dental problems	Cognitive behaviour therapy
Burning mouth syndrome	Tongue most commonly bilateral especially tip, lips, palate, buccal mucosa	Continuous in most instances	Burning, stinging, itchy sore, mild to severe	Sometimes eating aggravates, in others relieves	Dry mouth, abnormal taste, often depression, poor quality of life	Nil	Exclude other causes haematinics, blood glucose	Reassurance, education, CBT, possibly drugs for neuropathic pain
Trigeminal neuralgia	Unilateral trigeminal nerve most common second and third divisions extraoral and intraoral	Paroxysmal attacks of 2 s to minutes, refractory period between attacks, 10–30 attacks daily, may remit for weeks, months. Other types can have a longer pain that can last for hours	Sharp, shooting electric shock like, frightful, but in some aching, burning after pain, moderate to very severe	Light touch washing, cold wind, eating, brushing teeth, many attacks are evoked but some can be spontaneous	Fear if severe depression	Light touch evoked pain, rarely sensory changes	MRI	Anticonvulsants, surgery
Glossopharyngeal neuralgia	Unilateral deep in the ear and or back of tongue, tonsils, neck	Paroxysmal attacks of 2 s to minutes, recurrent throughout day, may remit for weeks, months	Sharp, shooting electric shock like, frightful, moderate to very severe	Swallowing, coughing, touch ear	Syncope rarely	Light touch provoked	MRI	Anticonvulsants, surgery
Short unilateral neuralgiform pain with autonomic features (SUNA)/ SUNCT conjunctival injection and tearing	Unilateral mainly first and second division trigeminal nerve	Rapid attacks lasting seconds to several minutes, up to 200 attacks daily, no refractory period between attacks rare for remission periods	Sharp, stabbing, moderate to severe	Mostly spontaneous, some light touch evoked	Tearing, red eye, eye oedema, rhinorrhoea, or blockage, redness cheek, ear fullness	During an attack may see some of the autonomics	MRI including pituitary fossa	Lamotrigine

Giant cell arteritis	Temporal region jaw area may be bilateral	Continuous often sudden onset	Dull aching throbbing but can be very severe if tongue claudication is occurring	Chewing	Visual disturbance, diplopia, loss of vision, malaise, fever, myalgia, weight loss, up to 40–60% have polymyalgia rheumatica	Scalp tenderness, abnormality of temporal artery, pulse absent, cyanosis of tongue if claudication present	ESR > 50 mm h ⁻¹ C reactive protein raised, temporal artery biopsy within 2 weeks of therapy	High dose corticosteroids minimum 40 mg daily
Post stroke pain	Ipsilateral to stroke often whole side of the face, periorbital	Continuous begins after a stroke within a few months but can be delayed	Aching, burning pricking, mild to moderate	Touch	Can occur in other areas, contralateral limbs	Dysesthesia, allodynia	CT MRI sensory testing	Tricyclic antidepressants, gabapentin, pregablin
Persistent (chronic) idiopathic facial pain	Non-anatomical extraoral and intraoral	Continuous but some report hours or days of no pain	Dull, aching, nagging sometimes sharp	Fatigue, stress	Other widespread pain, irritable bowel, significant life events	Nil	None	Tricyclic antidepressants, cognitive behaviour therapy

RCTs with respect to BMS are often of poor quality.⁵¹ CBT may be effective.⁵² There have been several RCTs evaluating the role of alpha lipoic acid (antioxidant), but the evidence is conflicting.^{53–57} One study combining alpha lipoic acid with gabapentin 300 mg reported the best outcome.⁵⁸ Topical clonazepam and capsaicin were shown to have some effect in a single short-term trial.⁵⁹ Systemic capsaicin for 1 month gave good results but resulted in significant gastric problems.⁶⁰ Topical benzydamine,⁶¹ trazadone,⁶² hypericum perforatum,⁶³ and lafutidine⁶⁴ have all been shown to have limited efficacy.

Trigeminal neuralgia and its variants

Trigeminal neuralgia is defined by the IASP as ‘a sudden usually unilateral severe brief stabbing recurrent episodes of pain in the distribution of one or more branches of the trigeminal nerve’; it has a profound effect on quality of life.¹ Although rare, is it the most frequent diagnosis proposed for unilateral episodic pain. Its clinical features are given in Table 2. In rare cases, trigeminal neuralgia is symptomatic of other conditions (e.g. tumours, mostly benign), multiple sclerosis. There is an increasing literature describing variants of trigeminal neuralgia termed type 2,⁶⁵ and/or trigeminal neuralgia with concomitant pain.⁶⁶ In these cases, there is more prolonged pain in between the sharp shooting attacks. In the classical types, the most common cause is neurovascular compression of the trigeminal nerve in or around the route entry zone whereas Type 2 may be of more central origin.⁶⁶

International guidelines and Cochrane reviews suggest that carbamazepine remains the primary drug of choice but oxcarbazepine is equally effective with fewer side-effects.^{67–70} Other drugs for which there is some evidence include lamotrigine and baclofen. Also, there has been a RCT of gabapentin combined with ropivacaine⁷¹ and a long-term cohort study of pregablin⁷² suggesting efficacy. However, in many patients, side-effects become intolerable or pain control becomes sub-optimal; in these cases, surgical interventions are considered. It is important that a neurosurgical opinion is obtained at an early stage. There are very few randomized control trials of surgery.⁷³ The only non-ablative (destructive) procedure is that of microvascular decompression; however, this is a major neurosurgical procedure in which access is gained to the posterior fossa in order to identify and remove a vascular compression of the trigeminal nerve. The nerve remains intact and so it is rare to get complications related to the trigeminal nerve, although 2–4% may suffer from hearing loss and, as with any major procedure, there is a 0.4% mortality. The chance of being pain free at 10 yr is 70%.⁷⁴ Other peripheral ablative procedures are available [e.g. neurectomy, cryotherapy, Gasserian ganglion (e.g. radiofrequency thermocoagulation, glycerol rhizotomy, balloon compression), and posterior fossa level (e.g. rhizotomy, Gamma Knife)]. All destroy to a greater or lesser extent the sensory fibres of the trigeminal nerve and hence result in varying degrees of sensory loss. These procedures

result in an ~50% chance of being pain free at 4 yr. Quality of life can be markedly improved provided there are no complications.

Glossopharyngeal neuralgia

Glossopharyngeal neuralgia has the same characteristics as trigeminal neuralgia except for location (Table 2). Pain can be experienced in the ear only and therefore confused with TMD; it may also be confined to the posterior part of the tongue. In rare cases, it can be associated with syncope because of anatomical proximity to the vagus. Management is the same as for trigeminal neuralgia. Microvascular decompression can be performed but is more difficult technically; there are very few reports of this.⁷⁵

Trigeminal autonomic cephalgias

Trigeminal autonomic cephalgias are a group of unilateral episodic pains, some of which can easily be mistaken for trigeminal neuralgia. These include: short unilateral neuralgiform pain with conjunctival injection, tearing, and redness (SUNCT); and short unilateral neuralgiform pain with cranial autonomic features (SUNA) (e.g. unilateral tearing, meiosis, sweating, nasal blockage or rhinorrhea, and ear fullness).⁷⁶ The aetiology may be different from trigeminal neuralgia which may account for poorer outcomes after surgery.⁷⁷ There are currently no RCTs or even large cohort data on the management of SUNA/SUNCT but treatments with anticonvulsants such as lamotrigine can be effective.⁷⁸

Vascular causes

It is essential to consider *giant cell arteritis* in any patient over the age of 50 who presents with pain in the temporal region which may mimic TMD as this can result in blindness if not rapidly treated. ESR and C reactive protein are typically raised and referral for biopsy should be requested urgently so that treatment with systemic steroids can be commenced.⁷⁹ Post-stroke pain can affect part or the whole of the face and its characteristics are described in Table 2. Management is along the same principles as neuropathic pain.⁸⁰

Persistent idiopathic facial pain PIFP (atypical facial pain)

When patients present with symptoms that do not fulfil any criteria currently available, then a diagnosis of persistent idiopathic facial pain (atypical facial pain) is made; the symptoms are described in Table 2. There is often a history of other chronic pain, poor coping skills, and mood disturbance. Management includes use of antidepressants often combined with cognitive behaviour therapy. It is important for the patient's pain to be acknowledged as real.^{81 82}

Declaration of interest

J.M.Z. undertook this work at UCL/UCLHT, and received a proportion of funding from the Department of Health's NIHR Biomedical Research Centre funding scheme.

References

- 1 Merskey H, Bogduk N. *Classification of Chronic Pain. Descriptors of Chronic Pain Syndromes and Definitions of Pain Terms*, 2nd Edn. Seattle: IASP Press, 1994
- 2 Anonymous. The international classification of headache disorders: 2nd Edn. *Cephalalgia* 2004; **24** (Suppl. 1): 9–160
- 3 Durham J, Steele JG, Wassell RW, Exley C. Living with uncertainty: temporomandibular disorders. *J Dent Res* 2010; **89**: 827–30
- 4 Zakrzewska JM. *Orofacial Pain*, 1st Edn. Oxford: Oxford University Press, 2009
- 5 Hegarty AM, Zakrzewska JM. Differential diagnosis for orofacial pain, including sinusitis, TMD, trigeminal neuralgia. *Dent Update* 2011; **38**: 396–408
- 6 Klasser GD, Balasubramaniam R, Epstein J. Topical review—connective tissue diseases: orofacial manifestations including pain. *J Orofac Pain* 2007; **21**: 171–84
- 7 Velly AM, Look JO, Carlson C, et al. The effect of catastrophizing and depression on chronic pain—a prospective cohort study of temporomandibular muscle and joint pain disorders. *Pain* 2011; **152**: 2377–83
- 8 Wiesinger B, Malker H, Englund E, Wanman A. Back pain in relation to musculoskeletal disorders in the jaw-face: a matched case-control study. *Pain* 2007; **131**: 311–9
- 9 Balasubramaniam R, de LR, Zhu H, Nickerson RB, Okeson JP, Carlson CR. Prevalence of temporomandibular disorders in fibromyalgia and failed back syndrome patients: a blinded prospective comparison study. *Oral Surg Oral Med Oral Pathol Oral Radiol Endod* 2007; **104**: 204–16
- 10 Velly AM, Look JO, Schiffman E, et al. The effect of fibromyalgia and widespread pain on the clinically significant temporomandibular muscle and joint pain disorders—a prospective 18-month cohort study. *J Pain* 2010; **11**: 1155–64
- 11 Anderson GC, John MT, Ohrbach R, et al. Influence of headache frequency on clinical signs and symptoms of TMD in subjects with temple headache and TMD pain. *Pain* 2011; **152**: 765–71
- 12 Schiffman E, Ohrbach R, List T, et al. Diagnostic criteria for headache attributed to temporomandibular disorders. *Cephalalgia* 2012; **32**: 683–92
- 13 Fillingim RB, Ohrbach R, Greenspan JD, et al. Potential psychosocial risk factors for chronic TMD: descriptive data and empirically identified domains from the OPPERA case-control study. *J Pain* 2011; **12**: T46–60
- 14 Fillingim RB, Slade GD, Diatchenko L, et al. Summary of findings from the OPPERA baseline case-control study: implications and future directions. *J Pain* 2011; **12**: T102–T107
- 15 Ohrbach R, Fillingim RB, Mulkey F, et al. Clinical findings and pain symptoms as potential risk factors for chronic TMD: descriptive data and empirically identified domains from the OPPERA case-control study. *J Pain* 2011; **12**: T27–T45
- 16 Dworkin SF, LeResche L. Research diagnostic criteria for temporomandibular disorders: review, criteria, examinations and specifications, critique. *J Craniomandib Disord* 1992; **6**: 301–55
- 17 Hasanain F, Durham J, Moufti A, Steen IN, Wassell RW. Adapting the diagnostic definitions of the RDC/TMD to routine clinical practice: a feasibility study. *J Dent* 2009; **37**: 955–62
- 18 Ohrbach R, Turner JA, Sherman JJ, et al. The research diagnostic criteria for temporomandibular disorders. IV: evaluation of psychometric properties of the Axis II measures. *J Orofac Pain* 2010; **24**: 48–62
- 19 Cairns B, List T, Michelotti A, Ohrbach R, Svensson P. JOR-CORE recommendations on rehabilitation of temporomandibular disorders. *J Oral Rehabil* 2010; **37**: 481–9

- 20 Petersson A. What you can and cannot see in TMJ imaging—an overview related to the RDC/TMD diagnostic system. *J Oral Rehabil* 2010; **37**: 771–8
- 21 Brister H, Turner JA, Aaron LA, Mancl L. Self-efficacy is associated with pain, functioning, and coping in patients with chronic temporomandibular disorder pain. *J Orofac Pain* 2006; **20**: 115–24
- 22 Friction JR, Ouyang W, Nixdorf DR, Schiffman EL, Velly AM, Look JO. Critical appraisal of methods used in randomized controlled trials of treatments for temporomandibular disorders. *J Orofac Pain* 2010; **24**: 139–51
- 23 List T, Axelsson S. Management of TMD: evidence from systematic reviews and meta-analyses. *J Oral Rehabil* 2010; **37**: 430–51
- 24 Craane B, Dijkstra PU, Stappaerts K, DE LA. Methodological quality of a systematic review on physical therapy for temporomandibular disorders: influence of hand search and quality scales. *Clin Oral Investig* 2012; **16**: 295–303
- 25 Ebrahim S, Montoya L, Busse JW, Carrasco-Labra A, Guyatt GH. The effectiveness of splint therapy in patients with temporomandibular disorders: a systematic review and meta-analysis. *J Am Dent Assoc* 2012; **143**: 847–57
- 26 Dahlstrom L, Carlsson GE. Temporomandibular disorders and oral health-related quality of life. A systematic review. *Acta Odontol Scand* 2010; **68**: 80–5
- 27 Gray R, Al-Ani Z. Risk management in clinical practice. Part 8. Temporomandibular disorders. *Br Dent J* 2010; **209**: 433–49
- 28 Michelotti A, Iodice G, Vollaro S, Steenks MH, Farella M. Evaluation of the short-term effectiveness of education versus an occlusal splint for the treatment of myofascial pain of the jaw muscles. *J Am Dent Assoc* 2012; **143**: 47–53
- 29 Cho SH, Whang WW. Acupuncture for temporomandibular disorders: a systematic review. *J Orofac Pain* 2010; **24**: 152–62
- 30 La TR, Goddard G, De-la-Hoz JL, et al. Acupuncture in the treatment of pain in temporomandibular disorders: a systematic review and meta-analysis of randomized controlled trials. *Clin J Pain* 2010; **26**: 541–50
- 31 Petrucci A, Sgolastra F, Gatto R, Mattei A, Monaco A. Effectiveness of low-level laser therapy in temporomandibular disorders: a systematic review and meta-analysis. *J Orofac Pain* 2011; **25**: 298–307
- 32 Melis M, Di GM, Zawawi KH. Low level laser therapy for the treatment of temporomandibular disorders: a systematic review of the literature. *Cranio* 2012; **30**: 304–12
- 33 Liu HX, Liang QJ, Xiao P, Jiao HX, Gao Y, Ahmetjiang A. The effectiveness of cognitive-behavioural therapy for temporomandibular disorders: a systematic review. *J Oral Rehabil* 2012; **39**: 55–62
- 34 Michelotti A, Steenks MH, Farella M, Parisini F, Cimino R, Martina R. The additional value of a home physical therapy regimen versus patient education only for the treatment of myofascial pain of the jaw muscles: short-term results of a randomized clinical trial. *J Orofac Pain* 2004; **18**: 114–25
- 35 Michelotti A, de WA, Steenks M, Farella M. Home-exercise regimes for the management of non-specific temporomandibular disorders. *J Oral Rehabil* 2005; **32**: 779–85
- 36 Mujakperuo HR, Watson M, Morrison R, Macfarlane TV. Pharmacological interventions for pain in patients with temporomandibular disorders. *Cochrane Database Syst Rev* 2010; **10**: CD004715
- 37 Plesh O, Curtis D, Levine J, McCall WD Jr. Amitriptyline treatment of chronic pain in patients with temporomandibular disorders. *J Oral Rehabil* 2000; **27**: 834–41
- 38 Ernberg M, Hedenberg-Magnusson B, List T, Svensson P. Efficacy of botulinum toxin type A for treatment of persistent myofascial TMD pain: a randomized, controlled, double-blind multicenter study. *Pain* 2011; **152**: 1988–96
- 39 Guo C, Shi Z, Revington P. Arthrocentesis and lavage for treating temporomandibular joint disorders. *Cochrane Database Syst Rev* 2009; **4**: CD004973
- 40 Rigon M, Pereira LM, Bortoluzzi MC, Loguercio AD, Ramos AL, Cardoso JR. Arthroscopy for temporomandibular disorders. *Cochrane Database Syst Rev* 2011; **5**: CD006385
- 41 O'connor AB, Dworkin RH. Treatment of neuropathic pain: an overview of recent guidelines. *Am J Med* 2009; **122**: S22–S32
- 42 Nixdorf DR, Drangsholt MT, Ettlin DA, et al. Classifying orofacial pains: a new proposal of taxonomy based on ontology. *J Oral Rehabil* 2011; **39**: 161–9
- 43 Benoliel R, Eliav E. Neuropathic orofacial pain. *Oral Maxillofac Surg Clin North Am* 2008; **20**: 237–54, vii
- 44 Renton T, Yilmaz Z. Profiling of patients presenting with post-traumatic neuropathy of the trigeminal nerve. *J Orofac Pain* 2011; **25**: 333–44
- 45 Benoliel R, Zadik Y, Eliav E, Sharav Y. Peripheral painful traumatic trigeminal neuropathy: clinical features in 91 cases and proposal of novel diagnostic criteria. *J Orofac Pain* 2012; **26**: 49–58
- 46 Baad-Hansen L. Atypical odontalgia—pathophysiology and clinical management. *J Oral Rehabil* 2008; **35**: 1–11
- 47 Koopman JS, Huygen FJ, Dieleman JP, de MM, Sturkenboom MC. Pharmacological treatment of neuropathic facial pain in the Dutch general population. *J Pain* 2009; **11**: 264–72
- 48 Forssell H, Jaaskelainen S, Tenovuo O, Hinkka S. Sensory dysfunction in burning mouth syndrome. *Pain* 2002; **99**: 41–7
- 49 Albuquerque RJ, de LR, Carlson CR, Okeson JP, Miller CS, Andersen AH. Cerebral activation during thermal stimulation of patients who have burning mouth disorder: an fMRI study. *Pain* 2006; **122**: 223–34
- 50 Sardella A, Lodi G, Demarosi F, Bez C, Cassano S, Carrassi A. Burning mouth syndrome: a retrospective study investigating spontaneous remission and response to treatments. *Oral Dis* 2006; **12**: 152–5
- 51 Zakrzewska JM, Forssell H, Glenny AM. Interventions for the treatment of burning mouth syndrome. *Cochrane Database Syst Rev* 2005; **1**: CD002779
- 52 Buchanan J, Zakrzewska J. Burning mouth syndrome. *Clin Evid* 2005; **14**: 1685–90
- 53 Femiano F, Gombos F, Scully C. Burning mouth syndrome: the efficacy of lipoic acid on subgroups. *J Eur Acad Dermatol Venereol* 2004; **18**: 676–8
- 54 Femiano F, Scully C. Burning mouth syndrome (BMS): double blind controlled study of alpha-lipoic acid (thioctic acid) therapy. *J Oral Pathol Med* 2002; **31**: 267–9
- 55 Cavalcanti DR, da Silveira FR. Alpha lipoic acid in burning mouth syndrome—a randomized double-blind placebo-controlled trial. *J Oral Pathol Med* 2009; **38**: 254–61
- 56 Carbone M, Pentenero M, Carozzo M, Ippolito A, Gandolfo S. Lack of efficacy of alpha-lipoic acid in burning mouth syndrome: a double-blind, randomized, placebo-controlled study. *Eur J Pain* 2009; **13**: 492–6
- 57 Lopez-Jornet P, Camacho-Alonso F, Molino-Pagan D. Prospective, randomized, double-blind, clinical evaluation of Aloe vera Barbadosis, applied in combination with a tongue protector to treat burning mouth syndrome. *J Oral Pathol Med* 2012; **42**: 295–301
- 58 Lopez-D'alessandro E, Escovich L. Combination of alpha lipoic acid and gabapentin, its efficacy in the treatment of Burning Mouth Syndrome: a randomized, double-blind, placebo controlled trial. *Med Oral Patol Oral Cir Bucal* 2011; **16**: e635–e640

- 59 Gremeau-Richard C, Woda A, Navez ML, et al. Topical clonazepam in stomatodynia: a randomised placebo-controlled study. *Pain* 2004; **108**: 51–7
- 60 Petrucci M, Lauritano D, De BM, Baldoni M, Serpico R. Systemic capsaicin for burning mouth syndrome: short-term results of a pilot study. *J Oral Pathol Med* 2004; **33**: 111–4
- 61 Sardella A, Uglietti D, Demarosi F, Lodi G, Bez C, Carrassi A. Benzylamine hydrochloride oral rinses in management of burning mouth syndrome. A clinical trial. *Oral Surg Oral Med Oral Pathol Oral Radiol Endod* 1999; **88**: 683–6
- 62 Tammiala-Salonen T, Forssell H. Trazodone in burning mouth pain: a placebo-controlled, double-blind study. *J Orofacial Pain* 1999; **13**: 83–8
- 63 Sardella A, Lodi G, Demarosi F, Tarozzi M, Canegallo L, Carrassi A. Hypericum perforatum extract in burning mouth syndrome: a randomized placebo-controlled study. *J Oral Pathol Med* 2008; **37**: 395–401
- 64 Toida M, Kato K, Makita H, et al. Palliative effect of lafutidine on oral burning sensation. *J Oral Pathol Med* 2009; **38**: 262–8
- 65 Limonadi FM, McCartney S, Burchiel KJ. Design of an artificial neural network for diagnosis of facial pain syndromes. *Stereotact Funct Neurosurg* 2006; **84**: 212–20
- 66 Obermann M, Yoon MS, Ese D, et al. Impaired trigeminal nociceptive processing in patients with trigeminal neuralgia. *Neurology* 2007; **69**: 835–41
- 67 Cruccu G, Gronseth G, Alksne J, et al. AAN-EFNS guidelines on trigeminal neuralgia management. *Eur J Neurol* 2008; **15**: 1013–28
- 68 Gronseth G, Cruccu G, Alksne J, et al. Practice parameter: the diagnostic evaluation and treatment of trigeminal neuralgia (an evidence-based review): report of the Quality Standards Subcommittee of the American Academy of Neurology and the European Federation of Neurological Societies. *Neurology* 2008; **71**: 1183–90
- 69 Wiffen PJ, Derry S, Moore RA, McQuay HJ. Carbamazepine for acute and chronic pain in adults. *Cochrane Database Syst Rev* 2011; **1**: CD005451
- 70 Wiffen PJ, Derry S, Moore RA. Lamotrigine for acute and chronic pain. *Cochrane Database Syst Rev* 2011; **2**: CD006044
- 71 Lemos L, Flores S, Oliveira P, Almeida A. Gabapentin supplemented with ropivacain block of trigger points improves pain control and quality of life in trigeminal neuralgia patients when compared with gabapentin alone. *Clin J Pain* 2008; **24**: 64–75
- 72 Obermann M, Yoon MS, Sensen K, Maschke M, Diener HC, Katsarava Z. Efficacy of pregabalin in the treatment of trigeminal neuralgia. *Cephalalgia* 2008; **28**: 174–81
- 73 Zakrzewska JM, Akram H. Neurosurgical interventions for the treatment of classical trigeminal neuralgia. *Cochrane Database Syst Rev* 2011; **9**: CD007312
- 74 Zakrzewska JM, Coakham HB. Microvascular decompression for trigeminal neuralgia: update. *Curr Opin Neurol* 2012; **25**: 296–301
- 75 Napenas JJ, Zakrzewska JM. Diagnosis and management of trigeminal neuropathic pains. *Pain Manag* 2011; **1**: 353–65
- 76 Cohen AS, Matharu MS, Goadsby PJ. Trigeminal autonomic cephalalgias: current and future treatments. *Headache* 2007; **47**: 969–80
- 77 Simms HN, Honey CR. The importance of autonomic symptoms in trigeminal neuralgia. Clinical article. *J Neurosurg* 2011; **115**: 210–6
- 78 May A, Leone M, Afra J, et al. EFNS guidelines on the treatment of cluster headache and other trigeminal-autonomic cephalalgias. *Eur J Neurol* 2006; **13**: 1066–77
- 79 Hassan N, Dasgupta B, Barraclough K. Giant cell arteritis. *Br Med J* 2011; **342**: d3019
- 80 Klit H, Finnerup NB, Jensen TS. Central post-stroke pain: clinical characteristics, pathophysiology, and management. *Lancet Neurol* 2009; **8**: 857–68
- 81 List T, Axelsson S, Leijon G. Pharmacologic interventions in the treatment of temporomandibular disorders, atypical facial pain, and burning mouth syndrome. A qualitative systematic review. *J Orofac Pain* 2003; **17**: 301–10
- 82 Aggarwal VR, Lovell K, Peters S, Javidi H, Joughin A, Goldthorpe J. Psychosocial interventions for the management of chronic orofacial pain. *Cochrane Database Syst Rev* 2011; **11**: CD008456

Handling editors: L. Colvin and D. J. Rowbotham