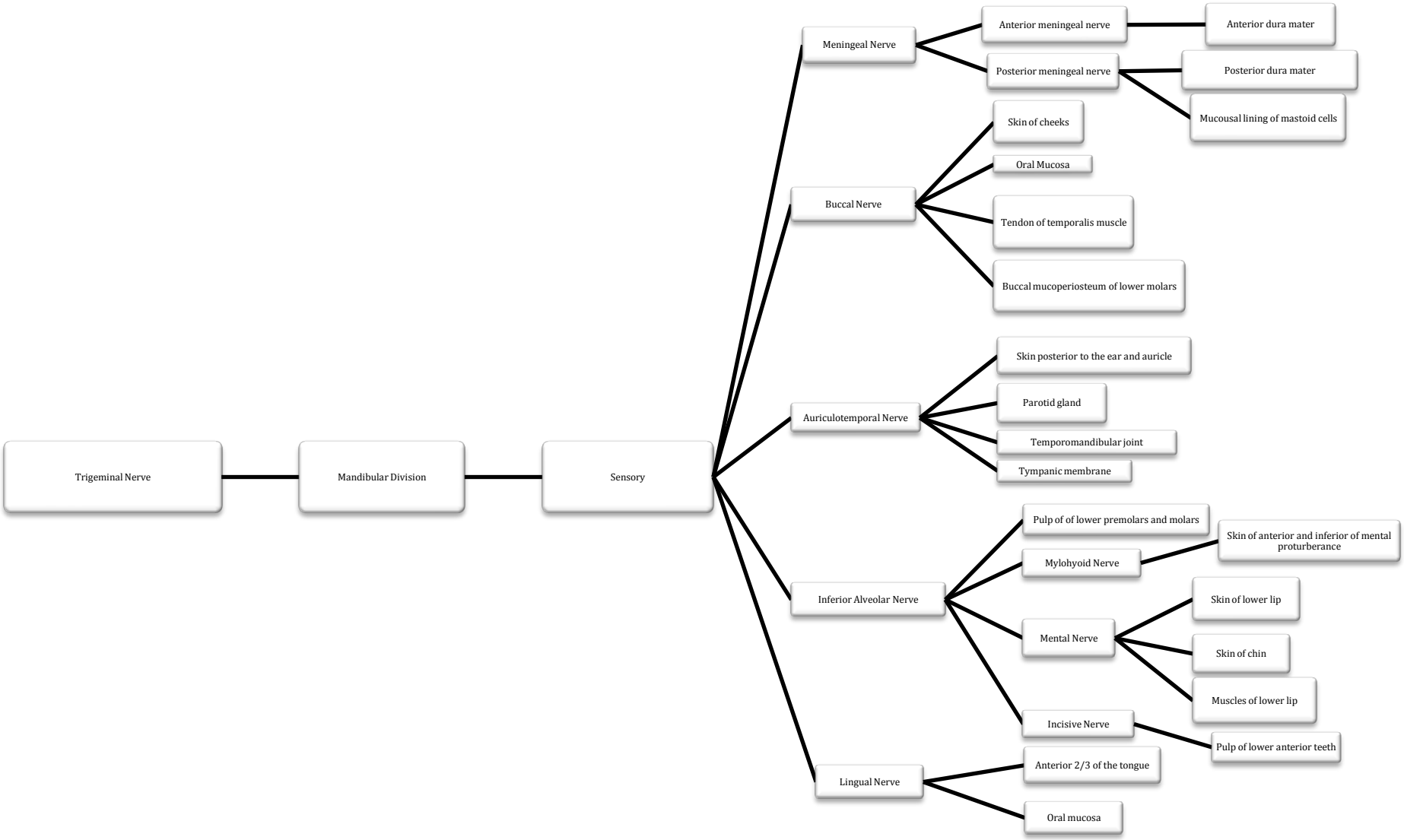
Trigeminal Nerve
Mandibular Division
Sensory
Meningeal Nerve
Anterior meningeal nerve
Anterior dura mater
Posterior meningeal nerve
Posterior dura mater
Mucousal lining of mastoid cells
Buccal Nerve
Skin of cheeks
Oral Mucosa
Tendon of temporalis muscle
Buccal mucoperiosteum of lower molars
Auriculotemporal Nerve
Skin posterior to the ear and auricle
Parotid gland
Temporomandibular joint
Tympanic membrane
Inferior Alveolar Nerve
Pulp of of lower premolars and molars
Mylohyoid Nerve
Skin of anterior and inferior of mental proturberance
Mental Nerve
Skin of lower lip
Skin of chin
Muscles of lower lip
Incisive Nerve
Pulp of lower anterior teeth
Lingual Nerve
Anterior 2/3 of the tongue
Oral mucosa