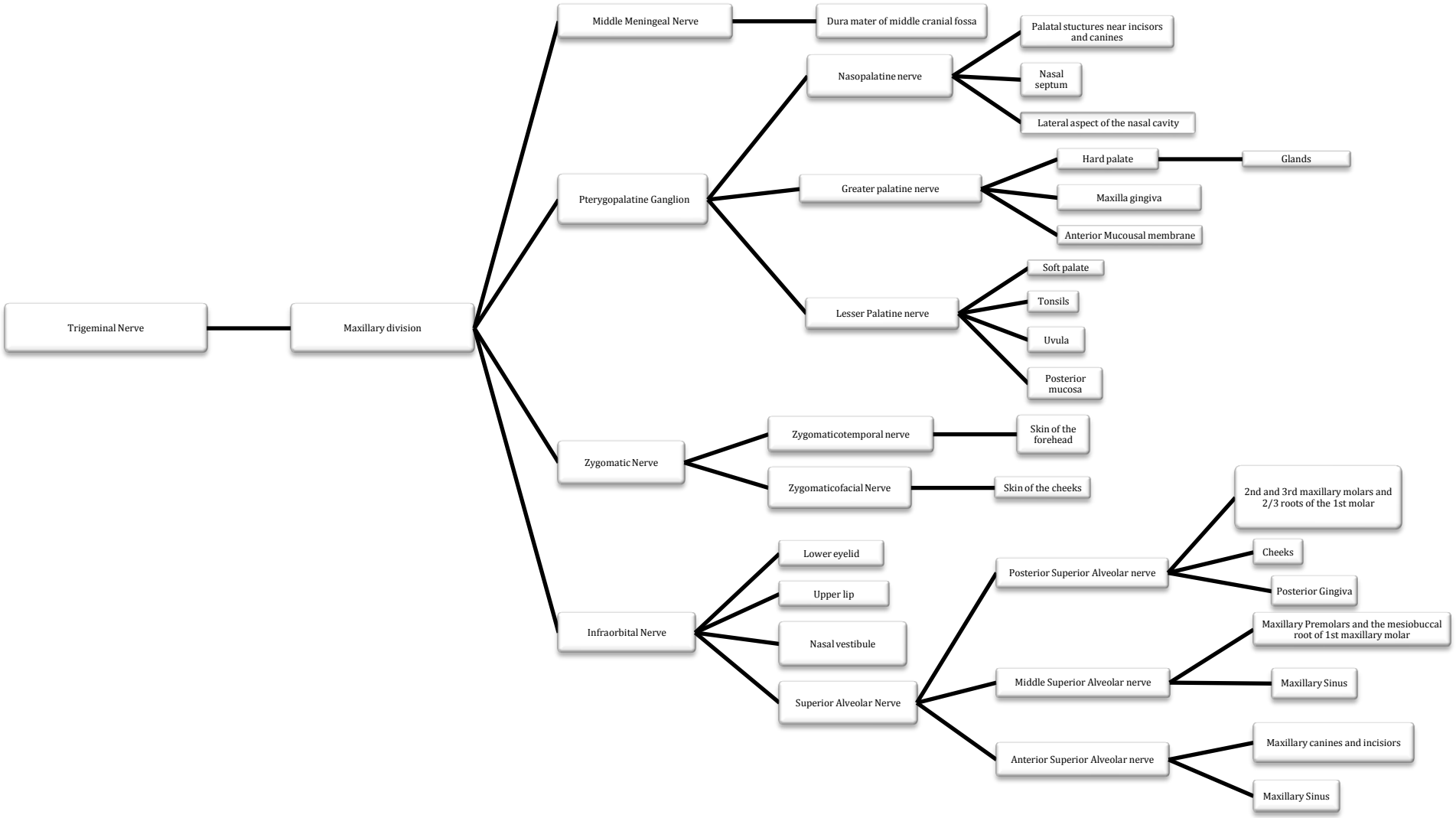
Trigeminal Nerve
Maxillary division
Middle Meningeal Nerve
Dura mater of middle cranial fossa
Pterygopalatine Ganglion
Nasopalatine nerve
Palatal stuctures near incisors and canines
Nasal septum
Lateral aspect of the nasal cavity
Greater palatine nerve
Hard palate
Glands
Maxilla gingiva
Anterior Mucousal membrane
Lesser Palatine nerve
Soft palate
Tonsils
Uvula
Posterior mucosa
Zygomatic Nerve
Zygomaticotemporal nerve
Skin of the forehead
Zygomaticofacial Nerve
Skin of the cheeks
Infraorbital Nerve
Lower eyelid
Upper lip
Nasal vestibule
Superior Alveolar Nerve
Posterior Superior Alveolar nerve
2nd and 3rd maxillary molars and 2/3 roots of the 1st molar
Cheeks
Posterior Gingiva
Middle Superior Alveolar nerve
Maxillary Premolars and the mesiobuccal root of 1st maxillary molar
Maxillary Sinus
Anterior Superior Alveolar nerve
Maxillary canines and incisiors
Maxillary Sinus